Increase awareness of colorectal cancer in younger population: A case study highlighting 29 year old female presenting aggressive form of colorectal cancer

NEW YORK INSTITUTE OF TECHNOLOGY
College of Osteopathic Medicine

Kriti Badola OMS III; Paul Cohen DO, MBA, DABFM, FAAFP

New York Institute of Technology College of Osteopathic Medicine

Learning Objectives

- Identifying potential risk factors for young onset colorectal cancer
- Explore barriers to early detection for young onset colorectal cancer

Introduction

Colorectal cancer(CRC) is the third most common cancer and cause of cancer death worldwide in both genders. Despite the prevalence of screening tests such as fecal occult blood test(FOBT) and colonoscopies allowing for early detection, deaths among people younger than age 55 have increased 2% per year from 2007-2016[1]. While the overall frequency of CRC has been declining, early onset CRC continues to rise representing a population of patients with unmet clinical needs. By the year 2030, the incidence of colon cancer is expected to double and rectal cancer incidence is expected to quadruple from 11% and 18% respectively[2]. Although some cases may have a hereditary basis, the majority appear to arise sporadically.

Needless to say this presents a serious threat to our healthcare system; this prompted the American Cancer Society(ACS) to change its recommendation from age 50 to age 45 for people at average risk in 2018. Currently routine colonoscopy is not recommended for individuals younger than age 45, resulting in advanced stages of colorectal cancer especially when diagnosed before age 20[3]. In this report, we describe 1 case diagnosed with colorectal adenocarcinoma at age 29. With this brief case review we would like to emphasize the alarming rise in the incidence of early onset colorectal cancer, and the importance of raising awareness and creating newer guidelines in response to the changing demographic of patients impacted by CRC.

Case Presentation

History of Present Illness:

- 29 year old female with no significant past medical history presents to PCP with 2 weeks of sudden onset blood in stool
- Denies fever, changes in weight, abdominal pain, nausea, vomiting.

Family History:

- Both parents and sister are alive and well
- No known history of chronic disease or cancer

Social History:

- Ex history of binge drinking for 8 years
- Ex history of tanning bed exposure several days a week for 8 years
- Denies tobacco use or other drug use

Medications:

- Zoloft, birth control

Physical Exam:

- Vital signs: afebrile, BP 116/80, HR 70, RR 16 BMI 23
- Exam: Abnormal rectal exam, +FOBT

Clinical Course

- Referred to gastroenterologist for colonoscopy given findings on rectal and FOBT
- Colonoscopy revealed partially obstructing mass in sigmoid colon 20 cm from anal verge(Figure 1)
- CT imaging revealed liver metastasis as well
- Eventual biopsy confirmed stage IV colorectal cancer
- Placed on Folfoxiri treatment regimen preceding liver resection
- After 12 cycles of Folfoxiri she underwent partial colectomy
- At diagnosis carcinoembryonic antigen(CEA) level was 77, and was reduced to 3.1 prior to surgery
- Currently patient is in remission and CEA, blood work, and imaging is continued to be monitored

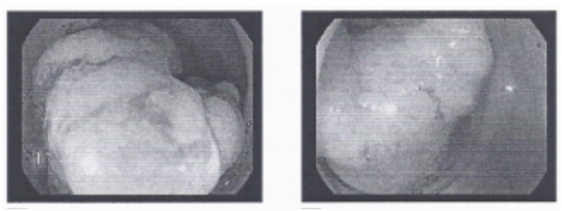

Figure 1: Panel A and B show obstructing tumor in sigmoid colon

Discussion

Colorectal cancer cannot be seen as a disease primarily affecting the elderly anymore. Symptoms at time of diagnosis for young onset patients include: rectal bleeding(51%), change in bowel habits(18%), abdominal pain(32%), weight loss(13%). Patients in one study often said they were misdiagnosed with more benign ailments such as hemorrhoids upon complaining of rectal bleeding to their primary care doctor[4]. If symptoms of rectal bleeding were presented in a patient over the age of 50, a more definitive evaluation would very likely take place.

In young patients almost two-thirds of rectal cancers are found in the distal colon, indicating screening may be in reach of a flexible sigmoidoscopy[4]. Referrals for sigmoidoscopes and colonoscopies should be used as appropriate for patients with unexplained persistent bleeding, and changes of bowel habits regardless of age. A cost effective analysis showed evaluation of the colon with asymptomatic rectal bleeding using a flexible sigmoidoscopy yielded the greatest life expectancy at costs comparable to that of a colon cancer screening[9]. As the face of colorectal cancer continues to evolve, physicians and other health professionals must be made aware of these changes to better guide and treat their patients.

Conclusion

Our case study is meant to spread, and increase the general awareness about the alarming rates of CRC and to emphasize the screening policies that are available for detection of CRC. Younger people need to be made aware of symptoms of colorectal cancer, and conversations about risks and prevention strategies should be discussed with primary care doctors during routine visits to better accommodate these changing trends across the globe.

References

1. American Cancer Society. Cancer Facts & Figures 2020. Atlanta, Ga: American Cancer Society; 2020.
2. Dana-farber.org. 2020. *Young-Onset Colorectal Cancer Center - Dana-Farber Cancer Institute* | Boston, MA . [online] Available at: <https://www.dana-farber.org/young-onset-colorectal-cancer-center/> [Accessed 26 May 2020].
3. Sultan I, Rodriguez-Galindo C, El-Taani H, et al. Distinct features of colorectal cancer in children and adolescents: a population-based study of 159 cases. Cancer. 2010;116(3):758-765. doi:10.1002/cncr.24777
4. Bosworth, Ted. "Https://Www.Gastroendonews.Com/In-the-News/Article/03-18/Researchers-Seek-Early-Signs-of-Young-Onset-C RC/47114." Www.Gastroendonews.Com , 9 Mar. 2018, www.gastroendonews.com/In-the-News/Article/03-18/Researchers-Seek-Early-Signs-of-Young-Onset-CRC/47114 . Accessed 26 May 2020.
5. Lewis JD, Brown A, Localio AR, Schwartz JS. Initial evaluation of rectal bleeding in young persons: a cost-effectiveness analysis. Ann Intern Med . 2002;136(2):99-110. doi:10.7326/0003-4819-136-2-200201150-00007