Osteopathic Manual Medicine for Ehlers Danlos Syndrome

Jayme D Mancini, DO, Ph.D

College of Osteopathic Medicine
Academic Health Care Center
December 8, 2017

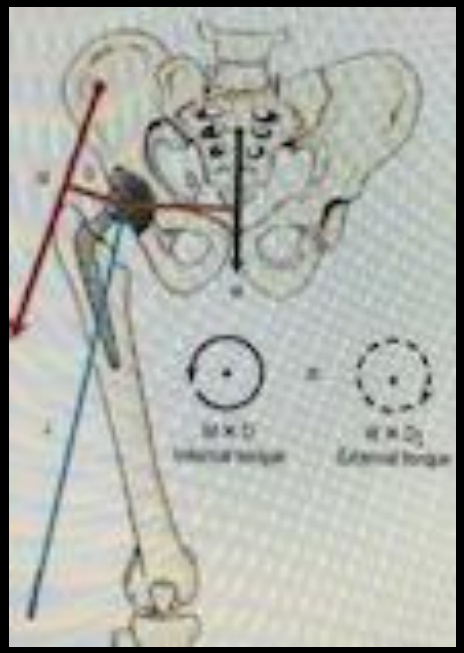

Osteopathic Principles & Practice

- Can be categorized into the five models of osteopathic treatment

- Used to develop a framework to integrate osteopathic manual treatments (OMT)

NYIT College of Osteopathic Medicine

BIOMECHANICAL MODEL

- The body as interconnected levers, pulleys, compression, and tension elements

- to identify physical barriers, or somatic dysfunctions, preventing the body from maintaining health and/or healing from injury

Biomechanics describes the relationship between structure and function

- The **biomaterial properties of tissues** such as bone, cartilage, muscles, tendons, and ligaments, are based on a hierarchy of **biomechanical properties from the molecular, cellular, tissue, and gross anatomic levels**.

- The gross biomechanical properties of the skeleton are defined by bony structure and the *attachment of muscles that produce forces across joints*.

- Normal movement in the spinal column is a composite of smaller motions of individual vertebrae.

- Restrictions of movement in one area can result in a compensatory increased mobility in others.

From: **The Concepts of Anatomy**

Foundations of Osteopathic Medicine, 3e, 2010

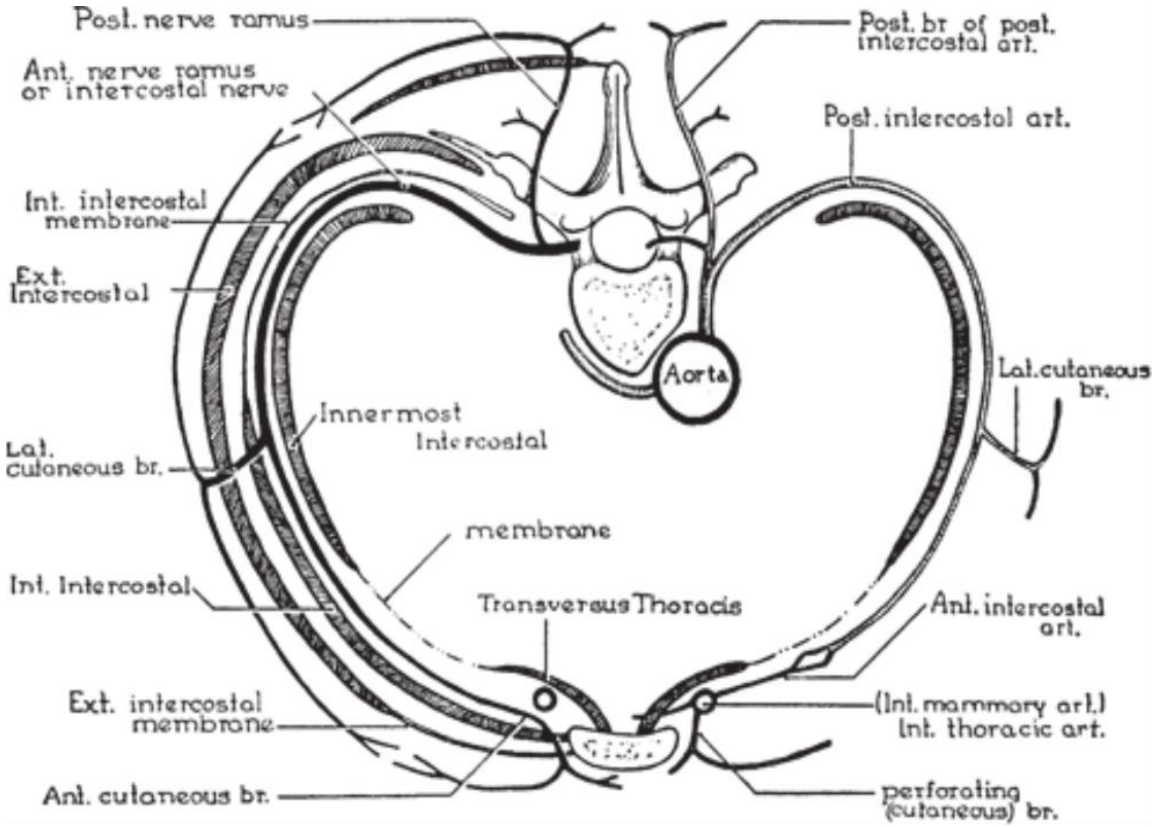

Legend:

Transverse section illustrating contents of a segmental level through the thorax.

From: **The Fascial System of the Body**

Foundations of Osteopathic Medicine, 3e, 2010

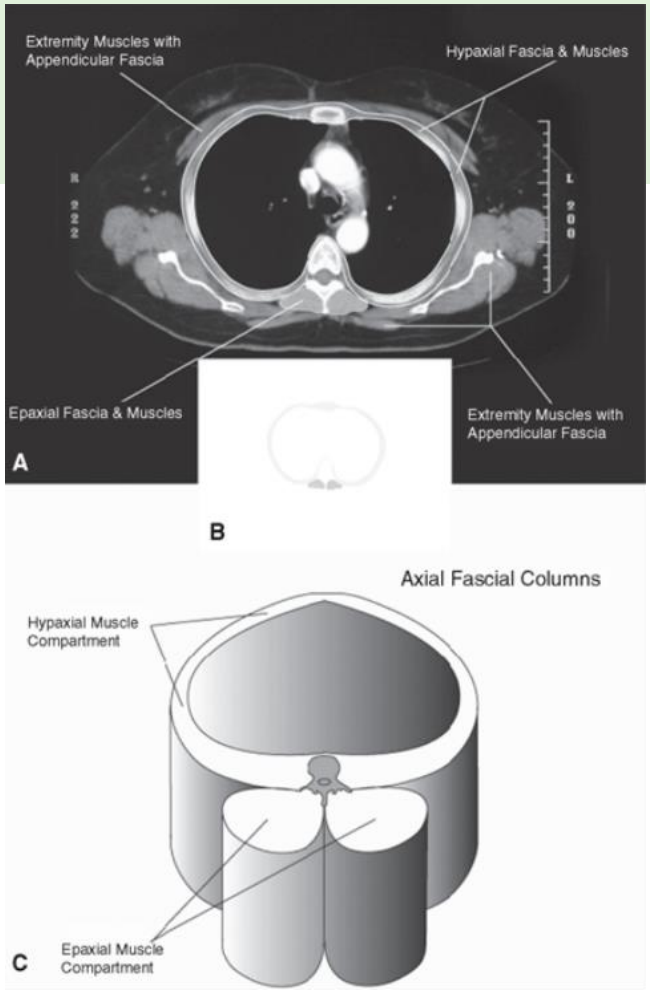

Legend:

This is an axial plane spiral CT taken through a male thorax. The white outline surrounding the axial muscles—hypaxial and epaxial—marks the course of the axial fascia. (Used with permission from the Willard/Carreiro Collection.)

From: **Biomechanics**

Foundations of Osteopathic Medicine, 3e, 2010

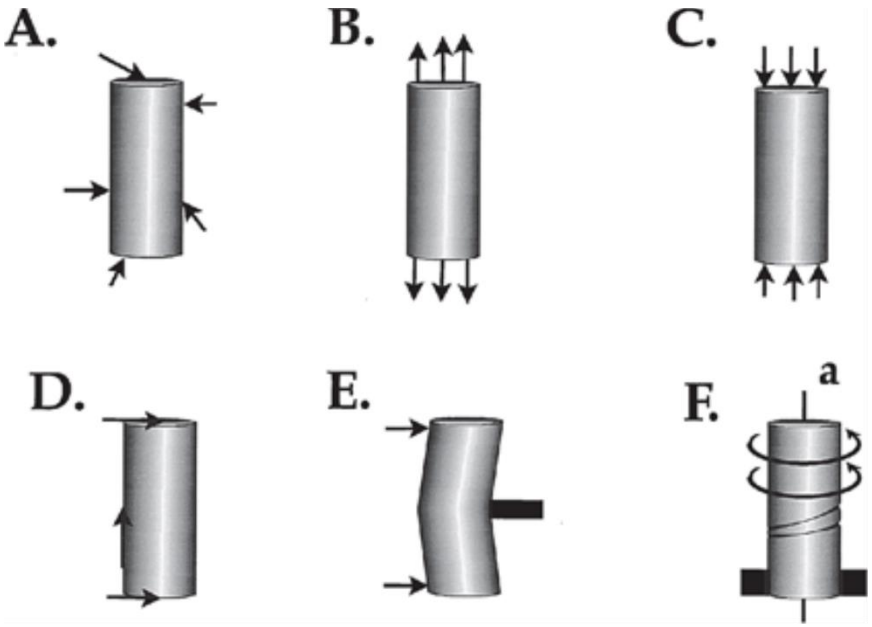

Legend:

A Stresses are forces acting from various orientations relative to the object. Stresses are named according to their action upon the object. B Tensile stresses act to stretch an object. C Compressive stresses compact the object. D Shear stresses act parallel to the surface of an object. E Bending stress acts to fold an object about an axis. F Torsion stresses twist an object about an axis.

The elastic properties of muscles, tendons, and ligaments allow them to store energy in some phases of movements for release during others.

Tissues are constantly remodeling in response to the stresses placed upon them.

Excessive stresses or inadequate responses to them result in ligament and tendon injury or disease in tissues.

Material Failure of Ligaments and Tendons Is Preceded by Microfailure of the Molecular Structural Elements

From: **The Fascial System of the Body**

Foundations of Osteopathic Medicine, 3e, 2010

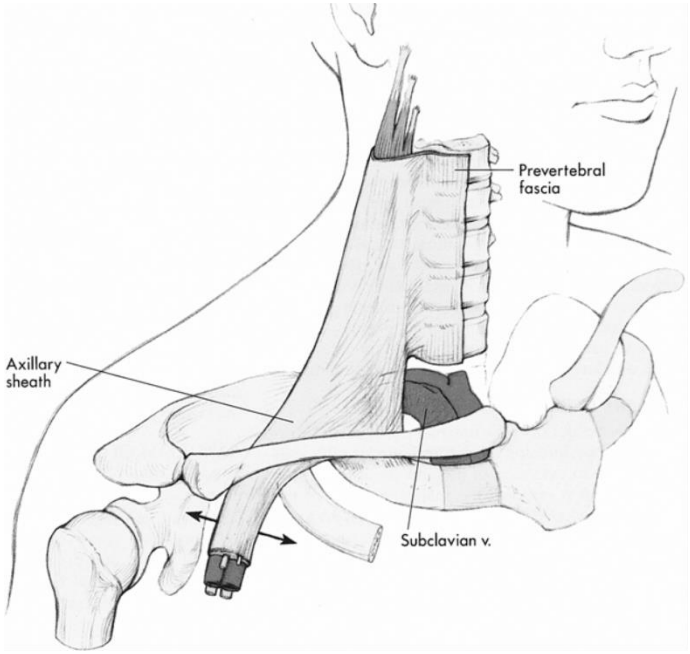

Legend:

The fascia surrounding the neurovascular bundle in the axial portion of the body extends outward into the extremity. (Taken from L. H. Mathers, R. A. Chase, J Dolph., E. F. Glasgow, and J. A. Gosling. Clinical Anatomy Principles, St Louis: Mosby, 1996.)

From: **Biomechanics**

Foundations of Osteopathic Medicine, 3e, 2010

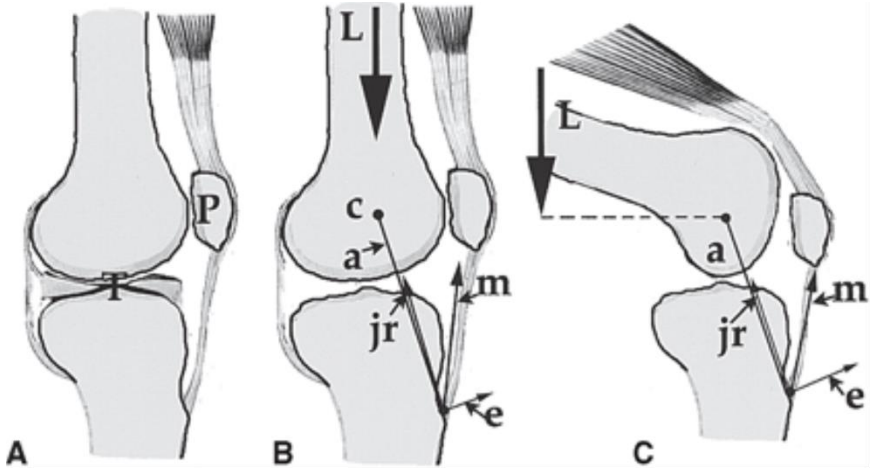

Legend:

A The knee joint consists of the tibiofibular (t) and patellofibular joints (p). B Moments produced by the load (L) of body weight require little muscle activity with the knee extended, but are maintained by a muscle contraction force through the patellar tendon (m), which produces moments through a moment arm (a) to the instant center of rotation of the joint (c). The moment is divided by the angle of muscle pull into a joint reaction force (jr) and an extending component (e). C With the knee flexed, the body weight produces a moment through the joint (c) that must be resisted by the extending component (e). In this instance, the patella increases the distance of the tendon from the femur to provide a more advantageous angle for the muscle contraction force on the tibia. This increases the proportion of the extension moment. Note that the position of the center of rotation (c) has changed slightly.

Aspects of Connective Tissue Disorders Addressed Through the Biomechanical Model

- Temporal mandibular joint dysfunction
- Spinal misalignments, spondylosis & degeneration of intervertebral discs
- Rib dysfunction
- Low back pain & sacroiliac joint dysfunction
- Abdominal wall strains
- Dysfunctions in the knees and ankles
- Dysfunctions in the wrist, elbow, and shoulder
- Loss of spring in the arches

- It is necessary to consider the biomechanical relationships of the body as a whole when attempting to define the consequences of injury or altered function of a body segment.

Goals of OMT for The Musculoskeletal System

- restoring normal muscle tone
- joint range of motion
- natural and functional alignment
- decreasing the sensation of pain (nociception) from joint distortion

The Neurological Model

- Sensorimotor, motor, and autonomic nervous system (ANS) control of the body

- OMT applied at the end muscle/organ or centrally at the spine or head.

From: **Autonomic Nervous System**

Foundations of Osteopathic Medicine, 3e, 2010

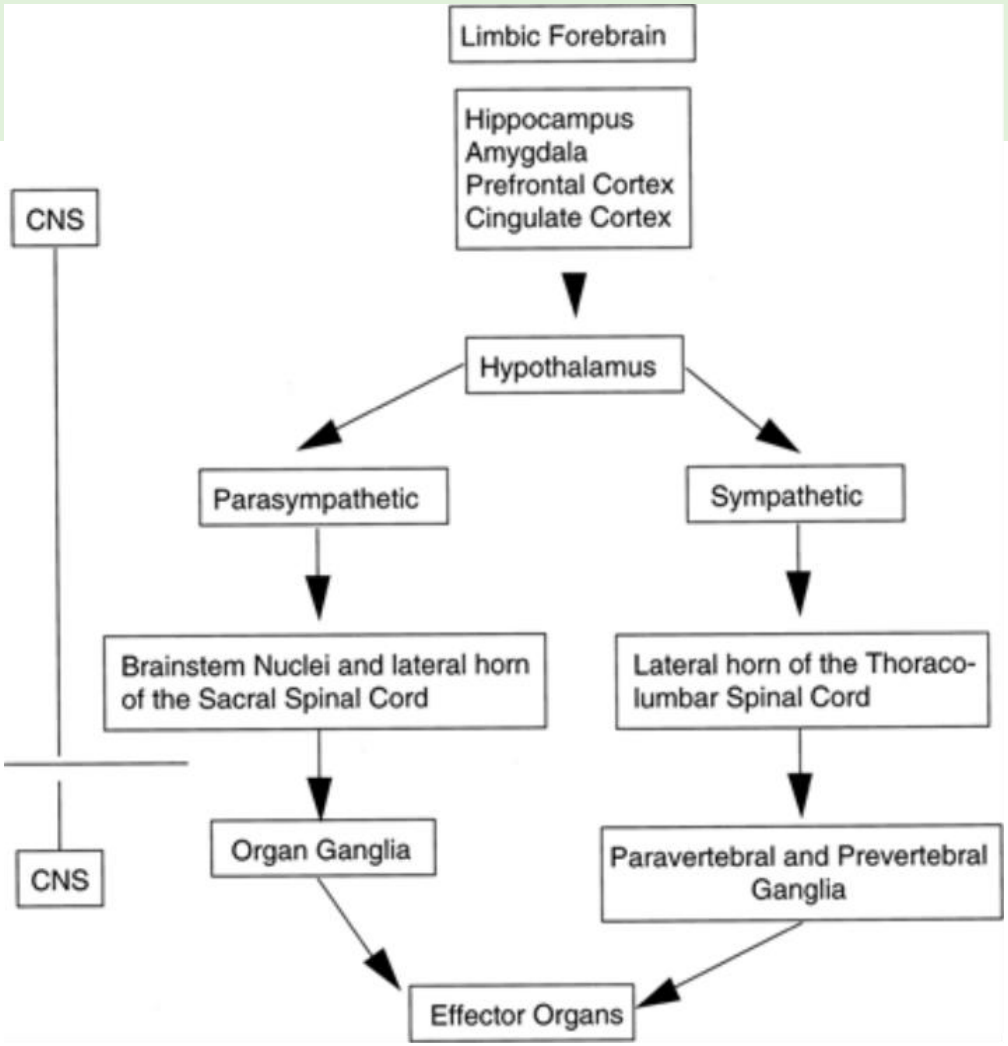

Legend:

General organization of the autonomic nervous system.

From: **Autonomic Nervous System**

Foundations of Osteopathic Medicine, 3e, 2010

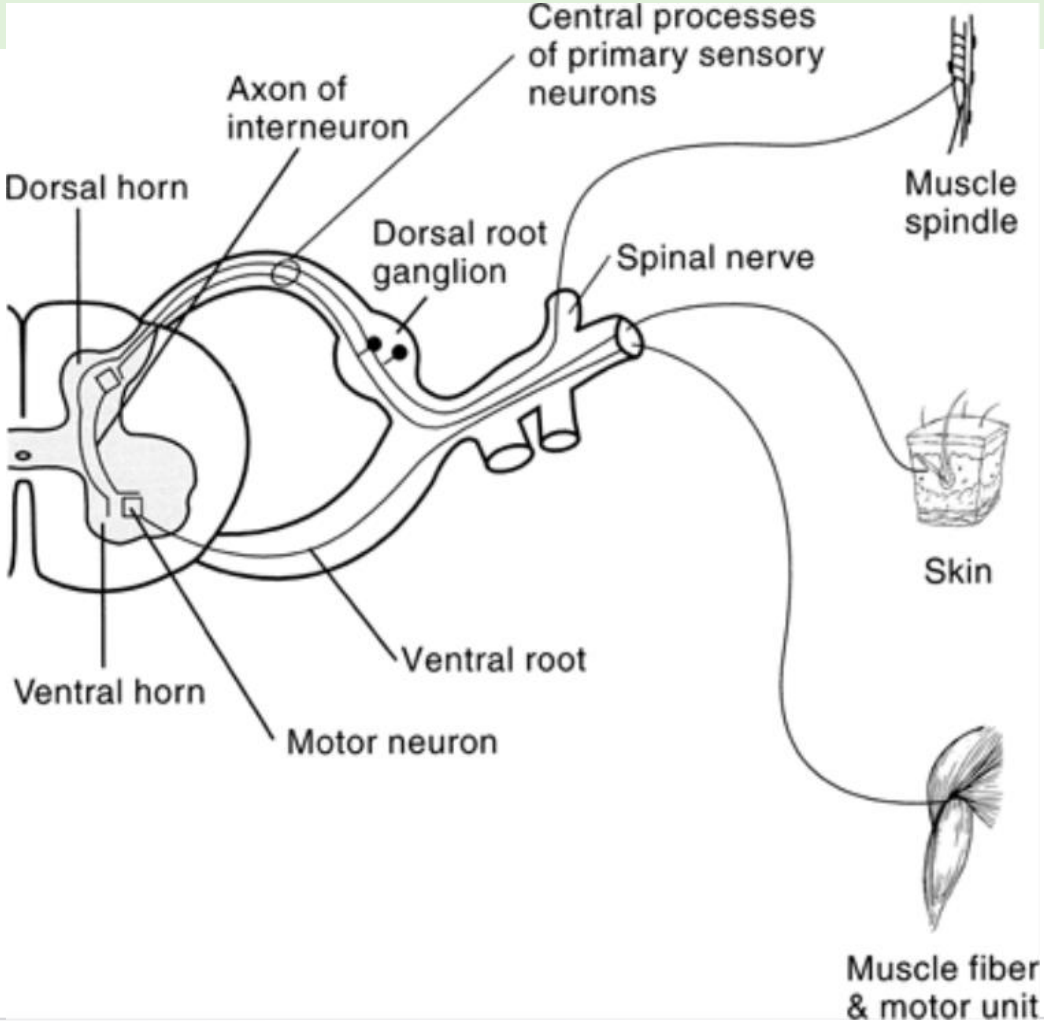

Legend:

Components of somatic reflex arc.

From: **Autonomic Nervous System**

Foundations of Osteopathic Medicine, 3e, 2010

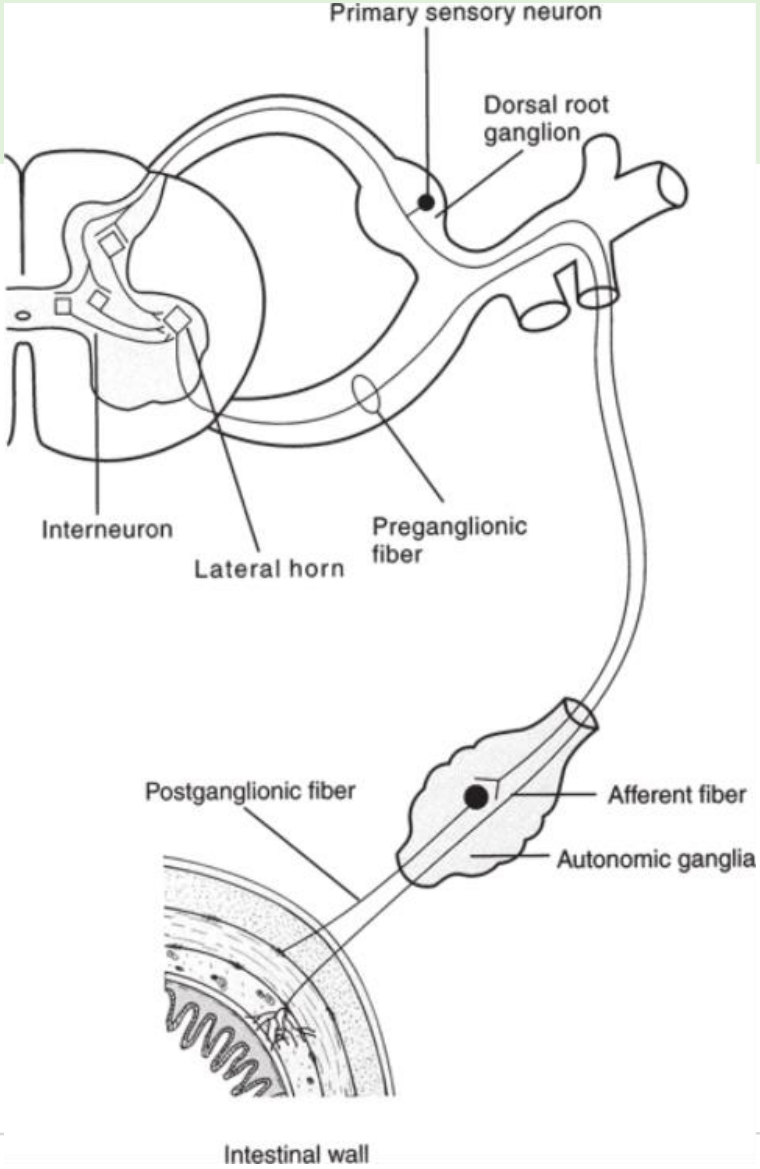

Legend:

Components of visceral reflex arc.

From: **Autonomic Nervous System**

Foundations of Osteopathic Medicine, 3e, 2010

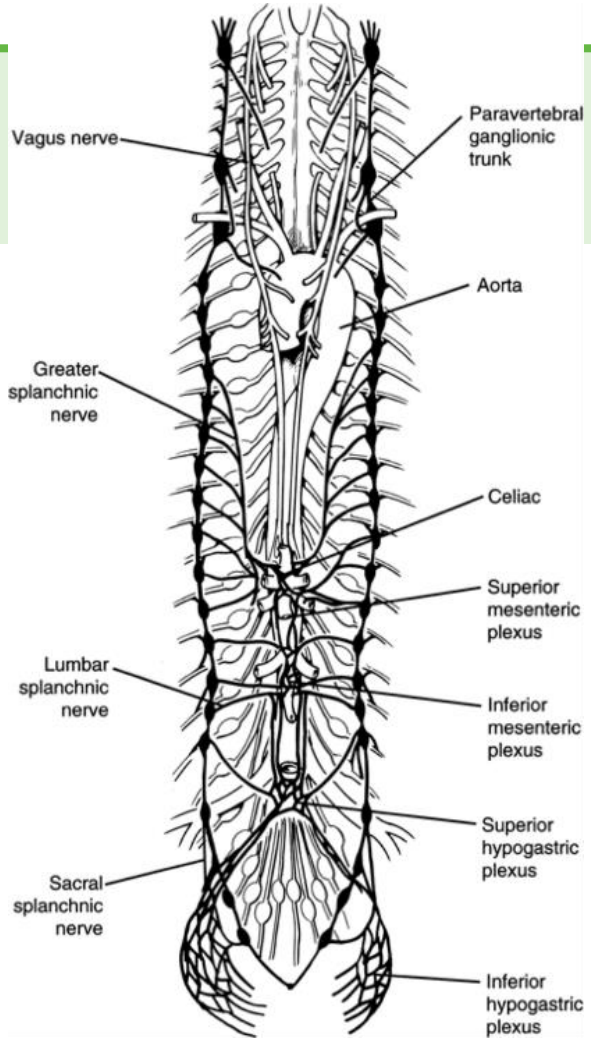

Legend:

Paravertebral ganglia (sympathetic trunk) lying along median axis of body. (From Rohen JW, Yokochi C. Color Atlas of Anatomy. New York, NY: Igaku-Shoin Medical Publishers, 1983, with permission.)

From: **Autonomic Nervous System**

Foundations of Osteopathic Medicine, 3e, 2010

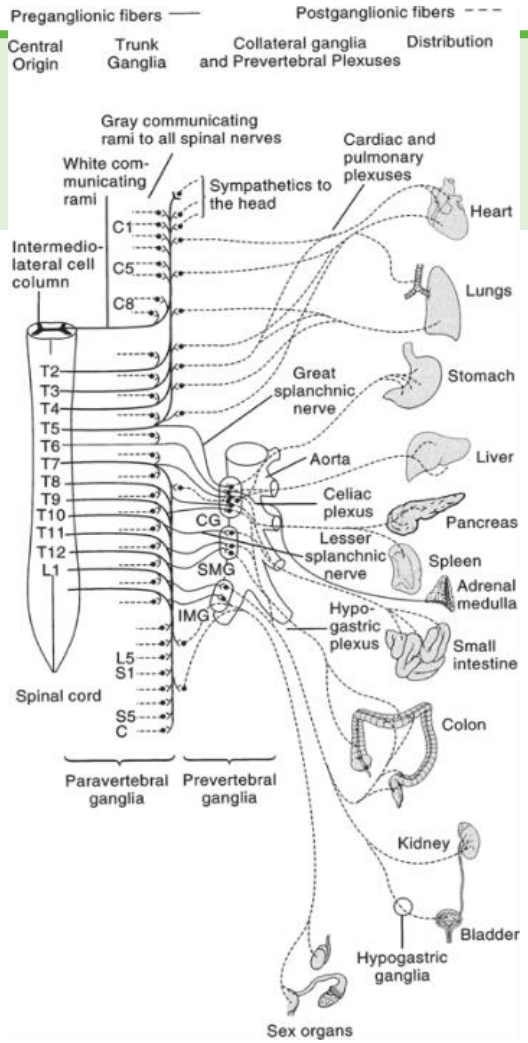

Legend:

Sympathetic division of peripheral autonomic system. CG, celiac ganglion; SMG, superior mesenteric ganglion; IMG, inferior mesenteric ganglion. (From Chusid JG. Correlative Neuroanatomy and Functional Neurology, Los Altos, CA: Lange Medical Publishers, 1985, with permission.)

Autonomic Nervous System Dysfunction

Dysautonomias

- Lightheadedness or feinting
  - Orthostatic intolerance
- Abdominal bloating, indigestion, other symptoms
  - Gastrointestinal paresis
- Coordination of the eyes
  - Double vision

From: **Autonomic Nervous System**

Foundations of Osteopathic Medicine, 3e, 2010

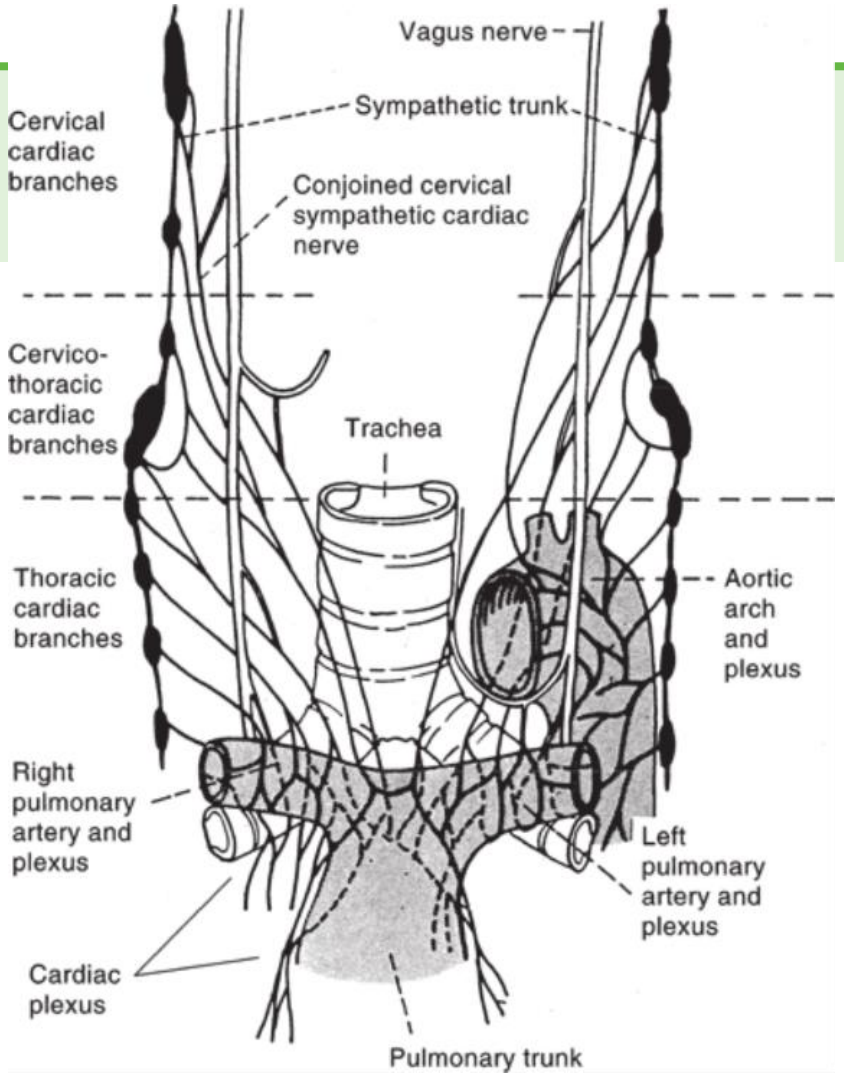

Legend:

Nerve supply of heart. (From Bonica JJ. General considerations of pain in the head. In: Bonica JJ, ed. The Management of Pain. Philadelphia, PA: Lea & Febiger, 1990, with permission.)

vasomotor autonomic nerve fibers

- The vasomotor fibers to the head and neck come from spinal segments T1-T4. Their axons travel superiorly in the sympathetic trunk to reach the cervical ganglia. Postganglionic axons follow the carotid vascular tree to reach the head and neck. Segments T1-T2 provide innervation for the brain and meninges; T2-T4 provides innervation to the vasculature of the face and neck.

- The vasomotor fibers to the upper extremity come from spinal segments T5-T7. Their axons course superiorly in the sympathetic trunk to reach the upper thoracic and lower cervical ganglia. Postganglionic axons join the spinal nerves of the brachial plexus to reach the vasculature of the upper extremity.

- The vasomotor fibers to the lower extremity come from spinal segments T10 through L2-L3. Their axons descend in the sympathetic trunk to reach the lower lumbar and sacral ganglia. Postganglionic axons join the spinal nerves of the lumbosacral plexus to reach the vasculature of the lower extremity.

From: **Autonomic Nervous System**

Foundations of Osteopathic Medicine, 3e, 2010

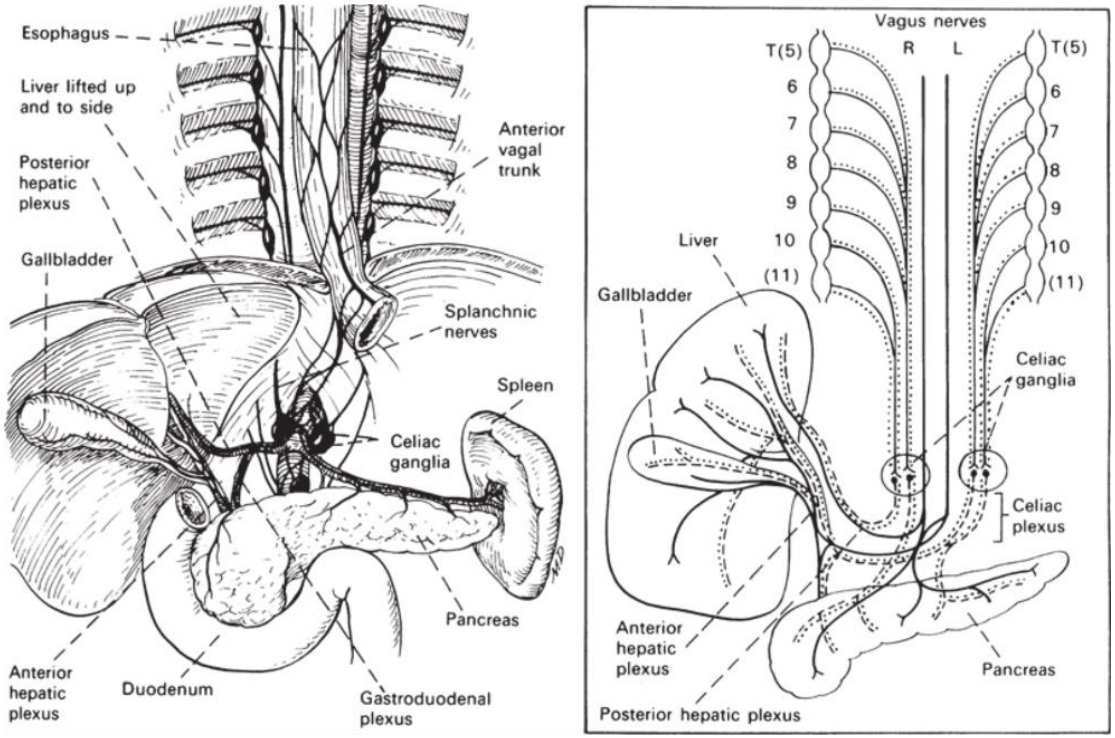

Legend:

Connections of celiac ganglion and innervation of stomach. (From Kimmey MB, Silverstein FE. Diseases of the gastrointestinal tract. In: Bonica JJ, ed. The Management of Pain. Philadelphia, PA: Lea & Febiger, 1990:1189, with permission.)

From: **Autonomic Nervous System**

Foundations of Osteopathic Medicine, 3e, 2010

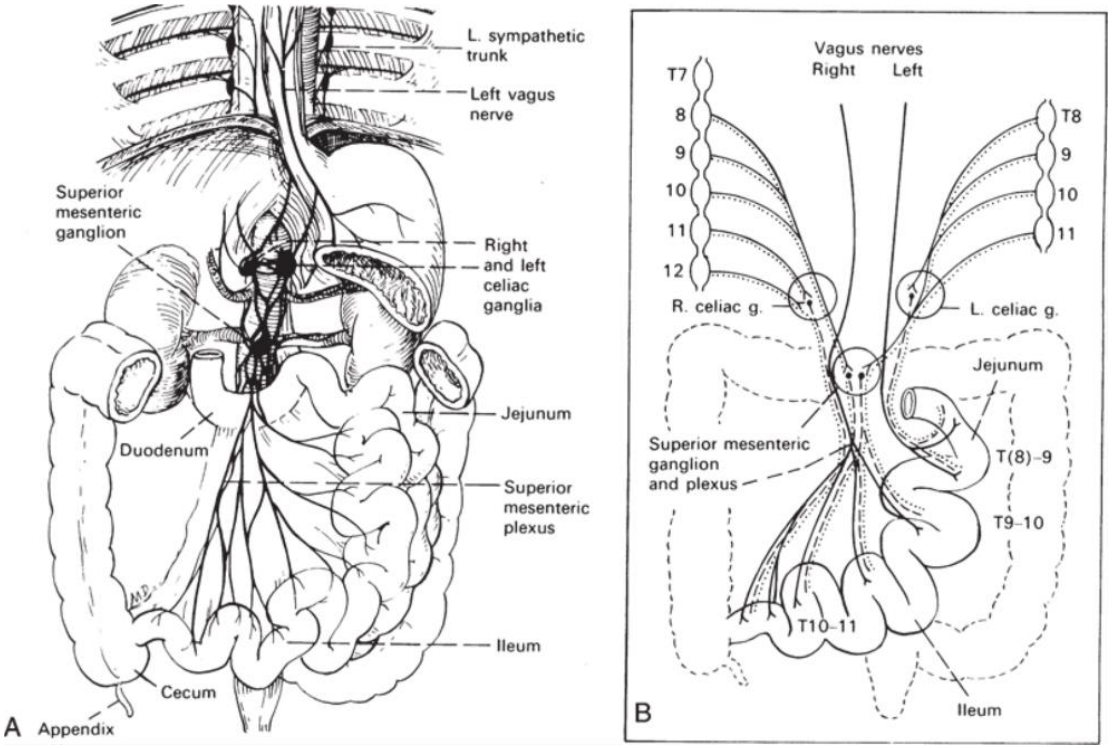

Legend:

Connections of superior mesenteric ganglion and the innervation of the small bowel. (From Kimmey MB, Silverstein FE. Diseases of the gastrointestinal tract. In: Bonica JJ, ed. The Management of Pain. Philadelphia, PA: Lea & Febiger, 1990:1198, with permission.)

From: **Autonomic Nervous System**

Foundations of Osteopathic Medicine, 3e, 2010

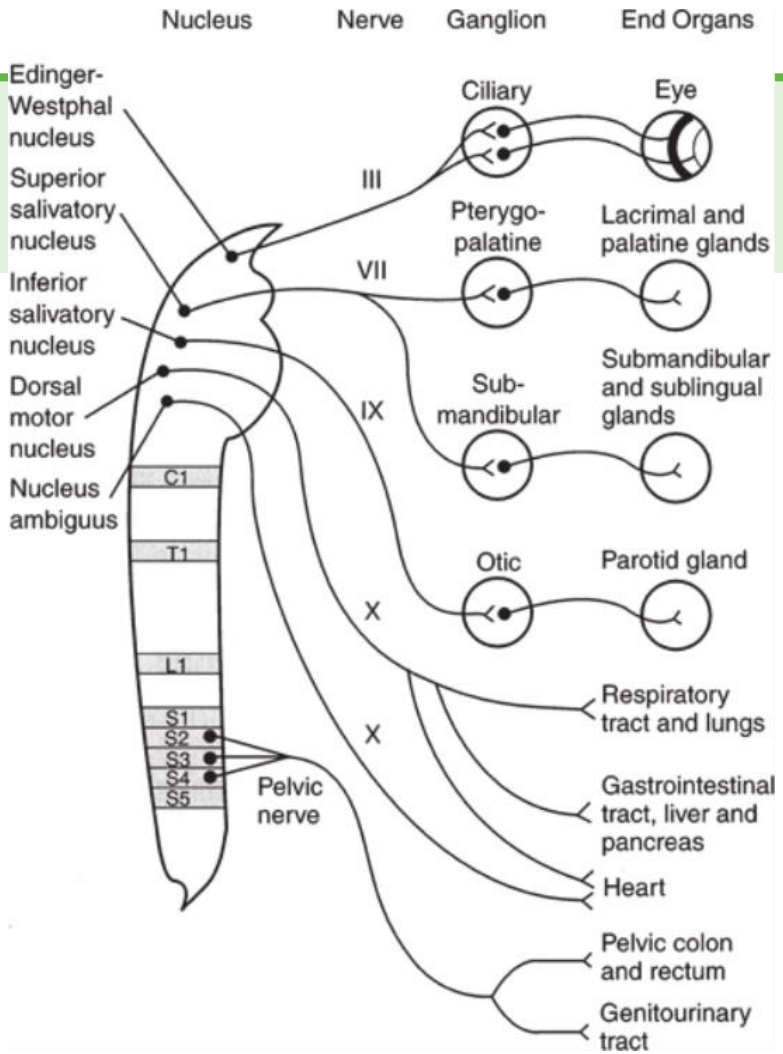

Legend:

Summary of parasympathetic nervous system emphasizing distribution of cranial nerves III, VII, IX, and X. (From Barron KD, Chokroverty S. Anatomy of the autonomic nervous system: brain and brainstem. In: Low PA, ed. Clinical Autonomic Disorders. Boston, MA: Little, Brown and Company, 1993, with permission.)

The respiratory-circulatory model

The proper motions of musculoskeletal structures linked to cardiovascular and pulmonary functions and the flow of lymphatic and cerebrospinal fluid

- Facilitating Breathing:
  - diaphragm, ribs and spine.
- Maintenance and transfer of pressure forces of pulmonary ventilation
  - Chest & Abdominal wall muscles, pelvic floor muscles
- Facilitating vascular functions:
  - Blood vessel wall constriction
  - lower leg muscles pump blood and lymph
- Maintenance and transfer of pressure forces
  - Blood vessel wall compliance

From: **Mechanics of Respiration**

Foundations of Osteopathic Medicine, 3e, 2010

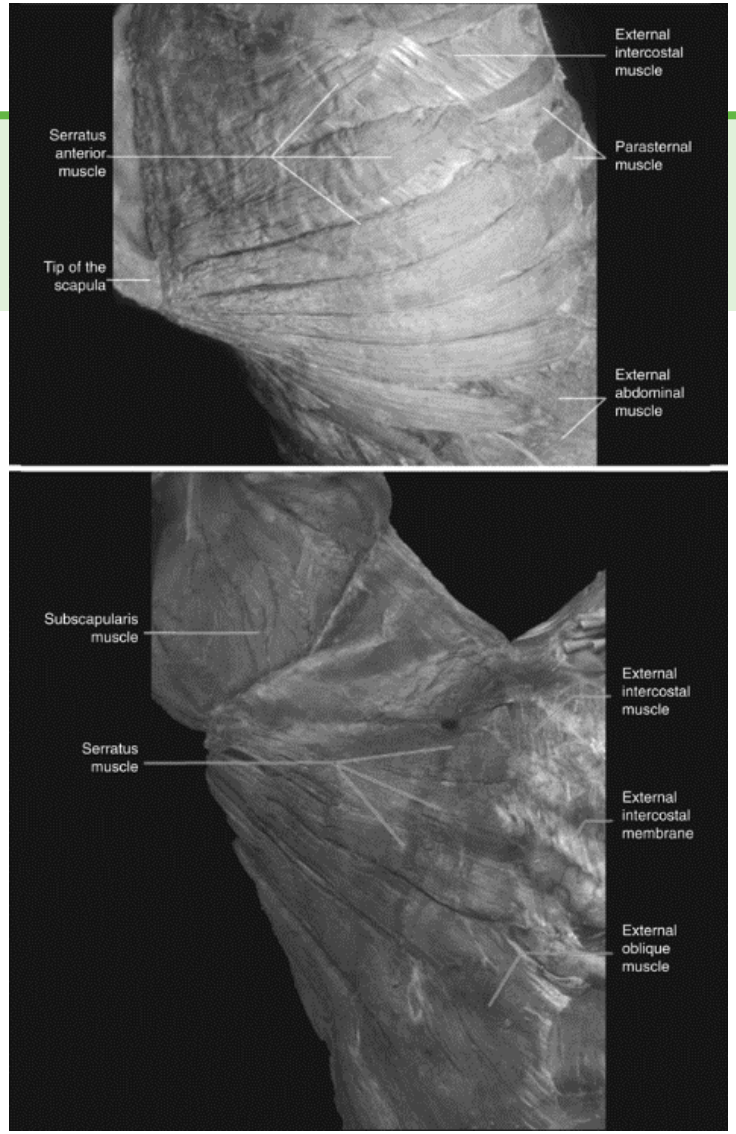

Legend:

The upper illustration is a lateral view of the serratus anterior in a specimen where the scapula has been freed from the body wall but sectioning the latissimus dorsi, trapezius and rhomboid muscles and cutting the clavicle. The scapula was then abducted as far laterally as possible to stretch the serratus to its full length. The lower illustration is an anterior view of a specimen prepared in a similar manner. The scapula has been fully abducted to expose the serratus anterior muscle. (Taken from the Willard/Carreiro Collection.)

From: **Mechanics of Respiration**

Foundations of Osteopathic Medicine, 3e, 2010

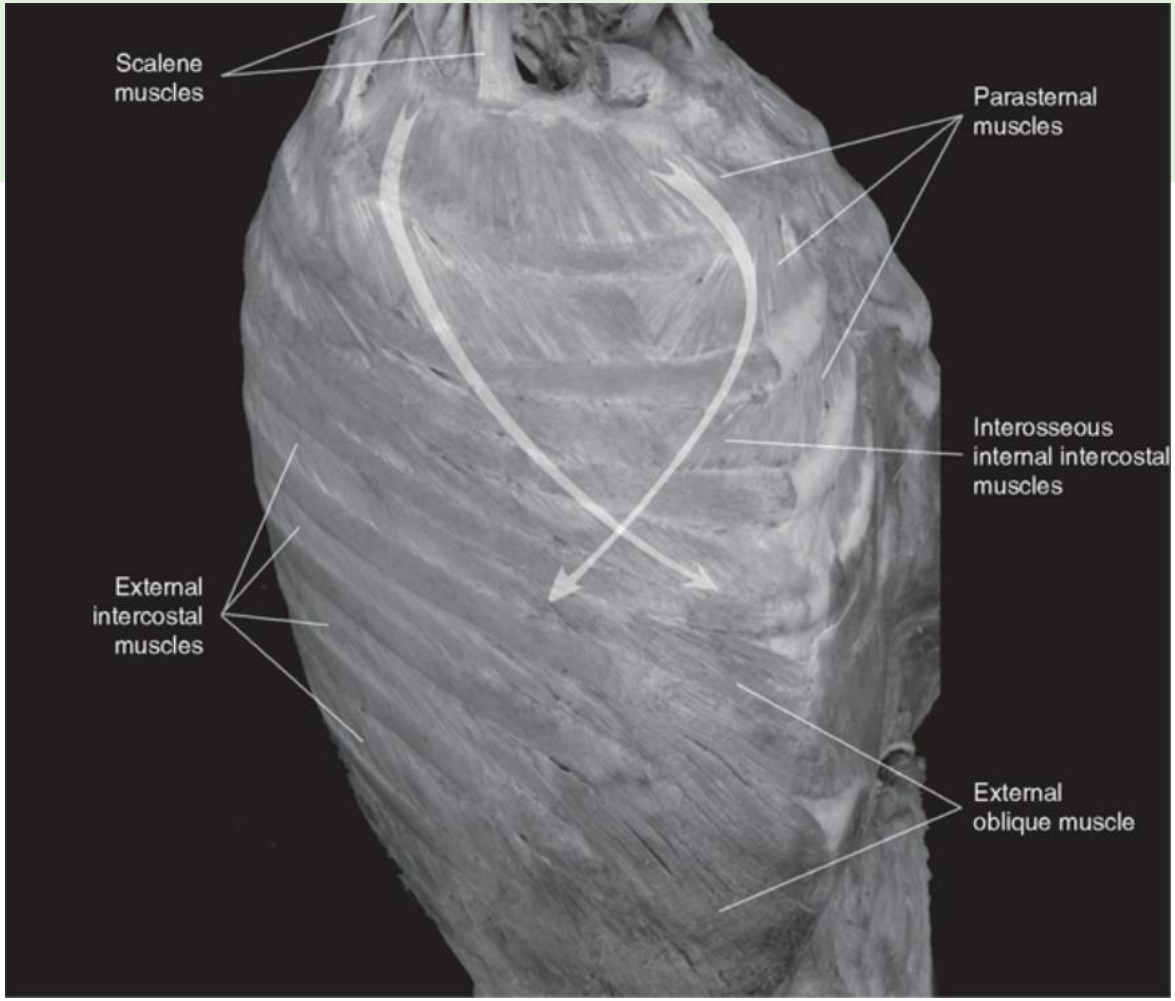

Legend:

This is a lateral view of the thorax demonstrating the helical spirals established by the external and internal intercostal muscles. The arrow that starts on the left represents the pitch of the spiral of the external intercostal muscle while the arrow beginning on the right represents the same for the internal intercostal muscle. (Taken from the Willard/Carreiro Collection.)

- The thoracoabdominal wall is a fibroelastic cylinder controlled by the respiratory muscles;

- Stable fixation of the upper border of the ribs facilitates inhalation while stable fixation of the lower border of the ribs enhances exhalation.

- The abdominal muscles play a role in stablizing/ fixing the lower border of the ribs as well as compressing the abdominal viscera and thereby expanding the zone of apposition to support the actions of the diaphragm.

- Structural changes in some respiratory muscles are seen at the molecular, cellular and gross structural levels in disease states such as scoliosis and kyphosis.

- These changes decrease motion, ultimately decreasing the ability of the respiratory mechanism to supply adequate pumping activity.

From: **Mechanics of Respiration**

Foundations of Osteopathic Medicine, 3e, 2010

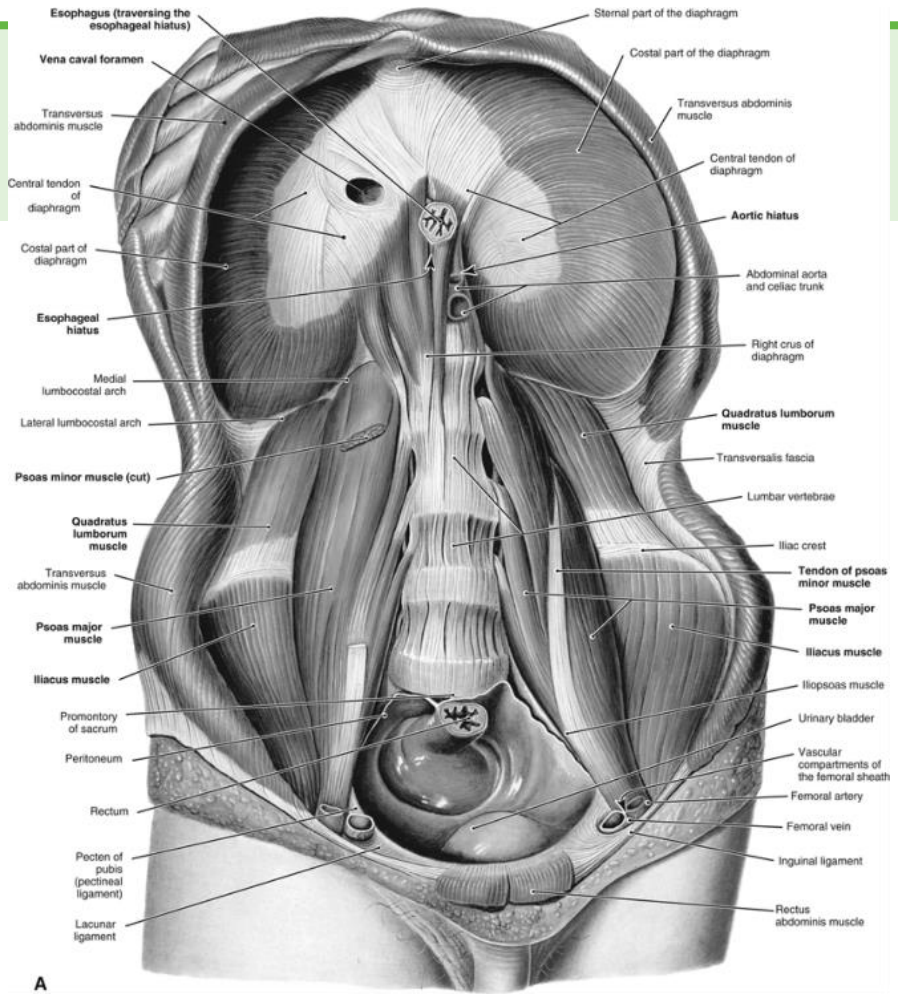

Legend:

The inferior surface of the thoracoabdominal diaphragm. In A. the abdomen has been opened to reveal the inferior surface of the diaphragm. In B. a similar approach has been taken with a human dissection. Abbreviations are as follows: Aor, hiatus for the aorta; Eso, hiatus for the esophagus; IVC, hiatus for the inferior vena cava. ((A) is taken from Clemente CD. Anatomy: A Regional Atlas of the Human Body. Baltimore: Williams & Wilkins; 1997; (B) is taken from the Willard/Carreiro Collection.)

From: **Mechanics of Respiration**

Foundations of Osteopathic Medicine, 3e, 2010

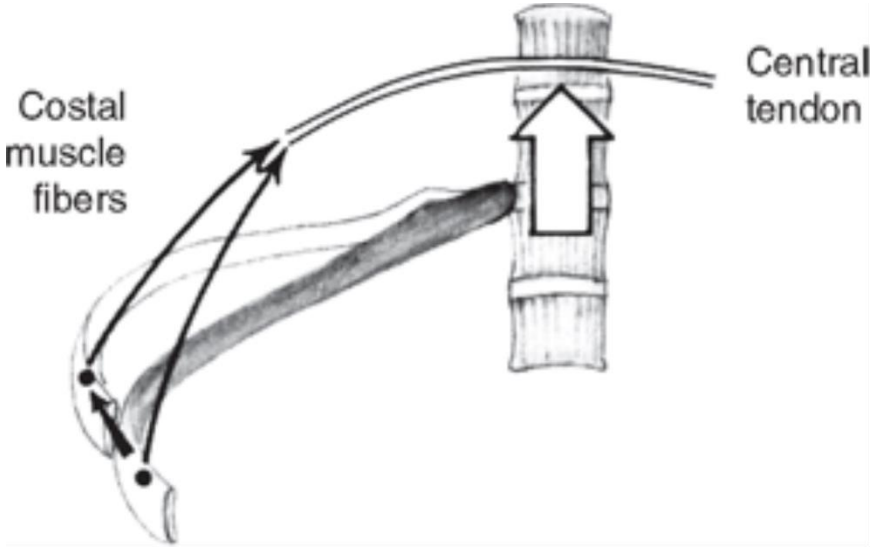

Legend:

The abdominal viscera (arrow) act as the fulcrum of the diaphragm allowing it to elevate the ribes. (Taken from De Troyer A and Estenne M. Functional anatomy of the respiratory muscles. Clin Chest Med N Am 1988;9:175–193.)

From: **Mechanics of Respiration**

Foundations of Osteopathic Medicine, 3e, 2010

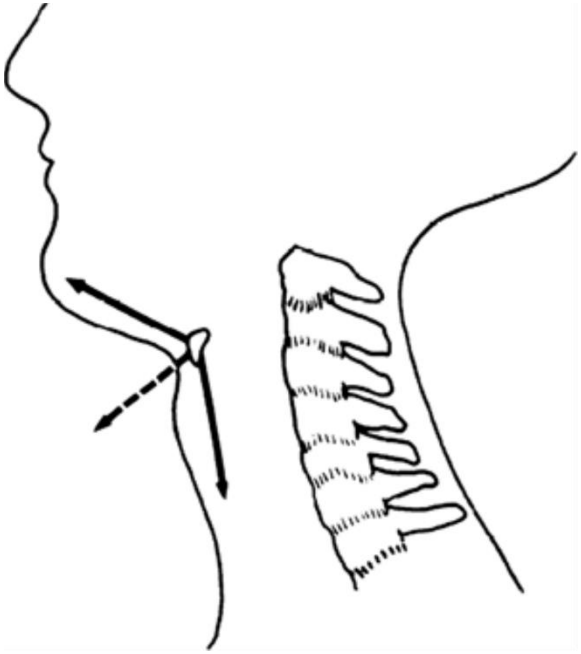

Legend:

This is a schematic view of the muscles supporting the hyoid bone. Simultaneous contraction of these muscle pulls the **hyoid** anteriorly opening the airway. (Taken from van de Graaff WB, Gottfried SB, Mitra J et al. Respiratory function of hyoid muscles and hyoid arch. J Appl Physiol 1984;57(1):197–204.)

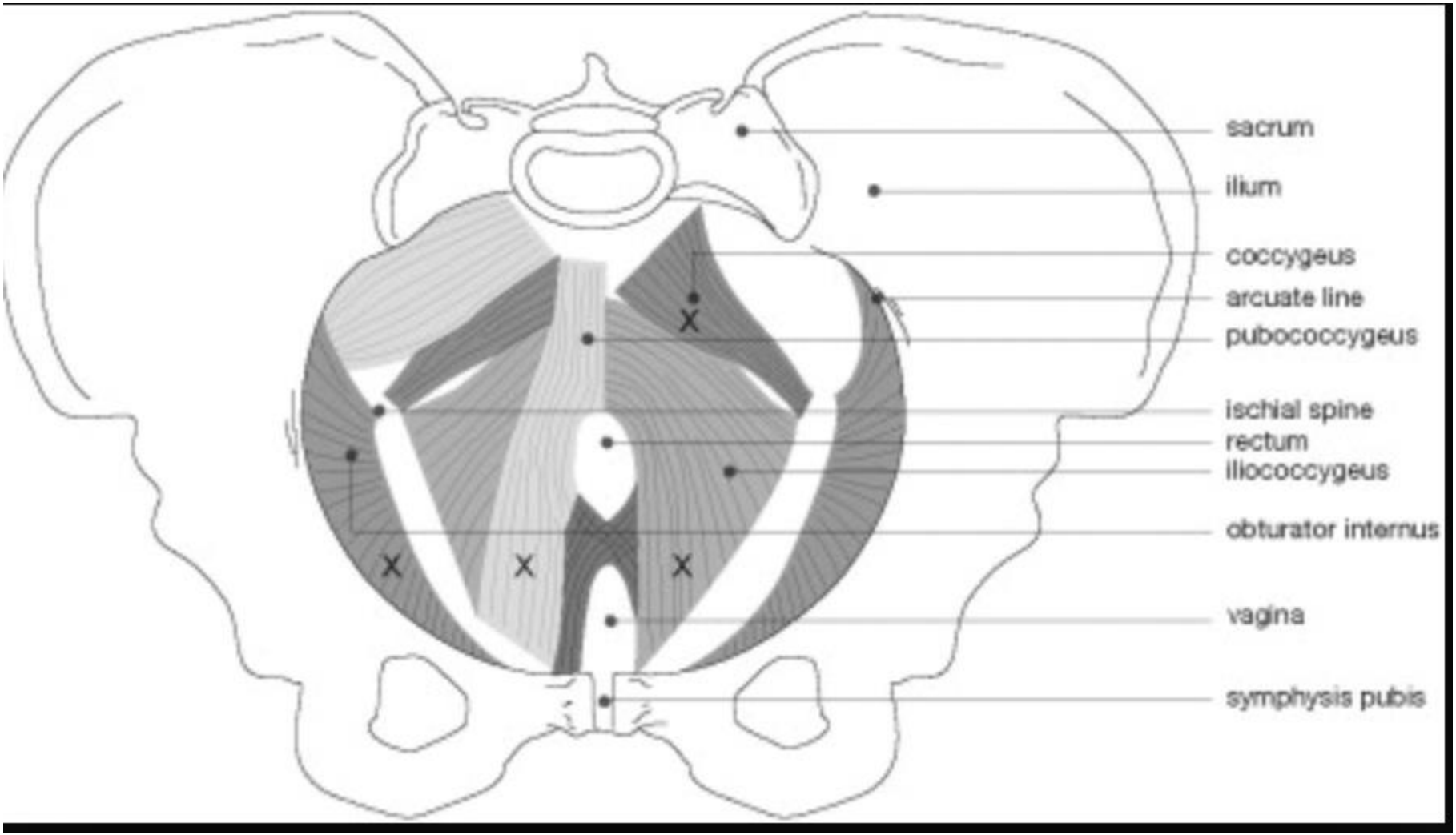
sacrum
ilium
coccygeus
arcuate line
pubococcygeus
ischial spine
rectum
iliococcygeus
obturator internus
vagina
symphysis pubis

Goal of OMT for Vasculature

- To recognize which piece of surrounding tissue might be
  - compressing or distorting an artery or
  - not compressing the veins in the calves
- Visualize the mechanical impediment to blood flow
- Utilize manual techniques to restore physiologic motion of that surrounding tissue

From: **The Fascial System of the Body**

Foundations of Osteopathic Medicine, 3e, 2010

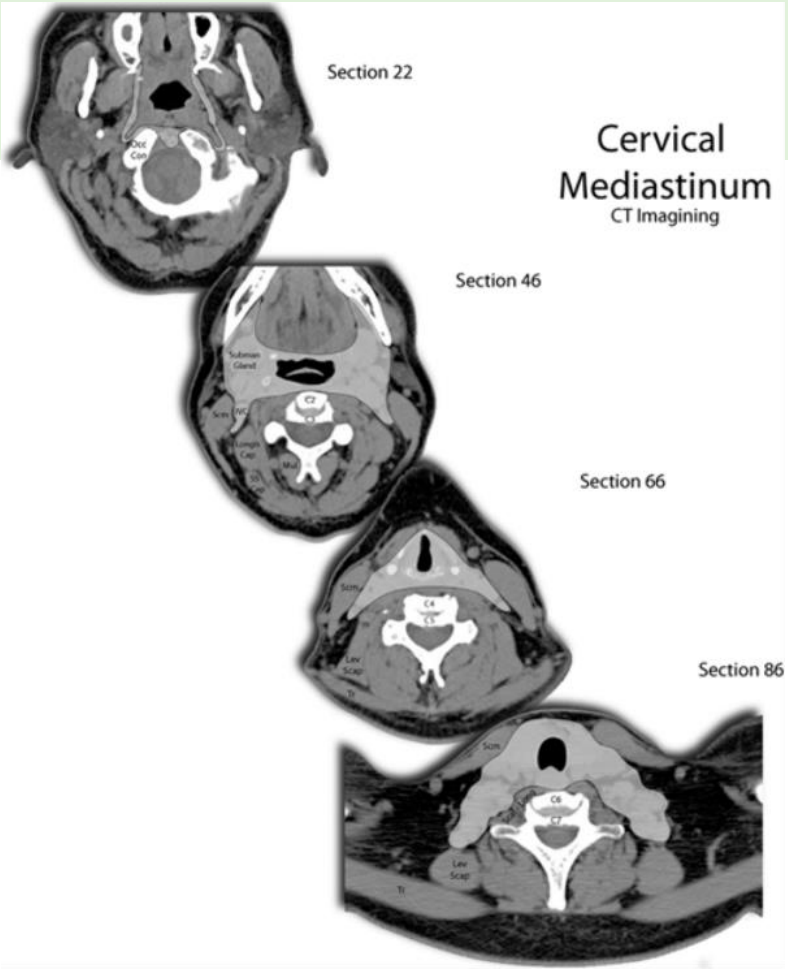

Legend:

Cervical Visceral Fascia. These images are a series of four cervical CT sections from one individual with the visceral fascia indicated by shading. This fascia begins as a flared opening (section 22 and 46) attached to the cranial base and consolidates into a continuous column of irregular connective tissue as it descends through the neck (sections 66 and 86).

From: **The Concepts of Anatomy**

Foundations of Osteopathic Medicine, 3e, 201

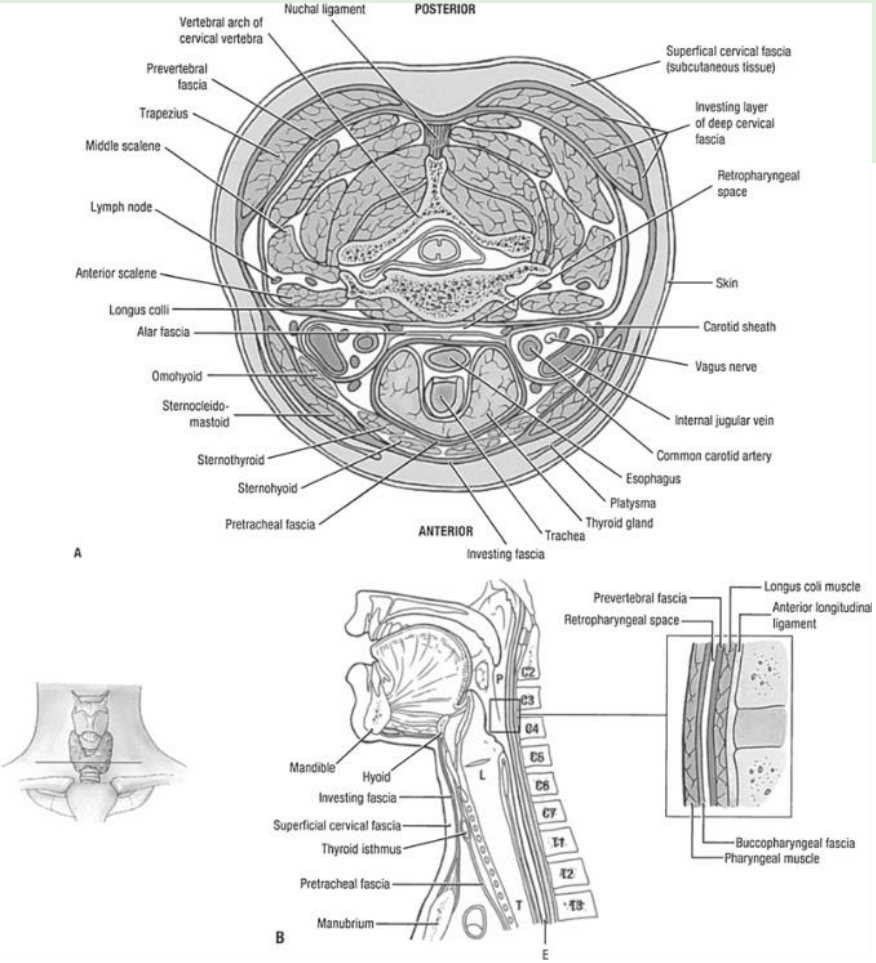

Legend:

Transverse section through the neck, illustrating the organization of the deep fascia. The deep fascia divides the neck into muscular, visceral, and neurovascular compartments.

Metabolic-Energy Model

- Biochemical, potential and kinetic energy dynamics aspects of physiology

- The main goal of this model is to improve
  - nutrient intake & absorbption
  - energy production
  - Efficient use of energy

From: **Postural Considerations in Osteopathic Diagnosis and Treatment**

Foundations of Osteopathic Medicine, 3e, 2010

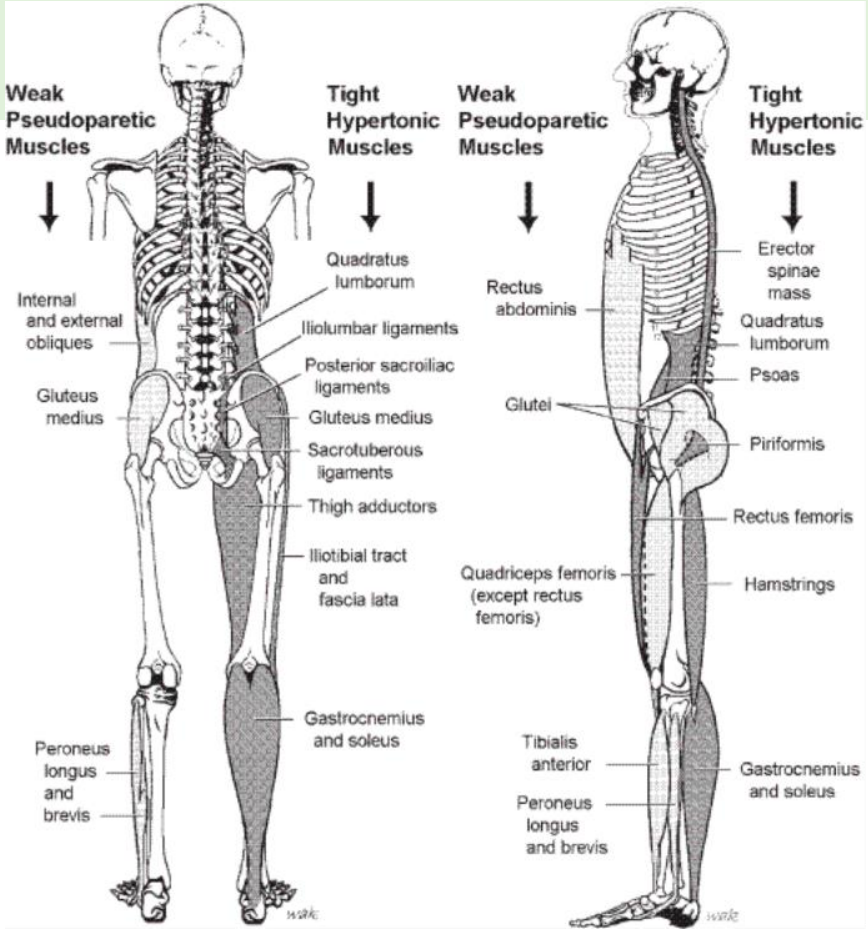

Legend:

A postural pattern of tight and weak muscles or of myofascial trigger points. (Courtesy of William Kuchera, D.O., F.A.A.O.)

From: **Postural Considerations in Osteopathic Diagnosis and Treatment**

Foundations of Osteopathic Medicine, 3e, 2010

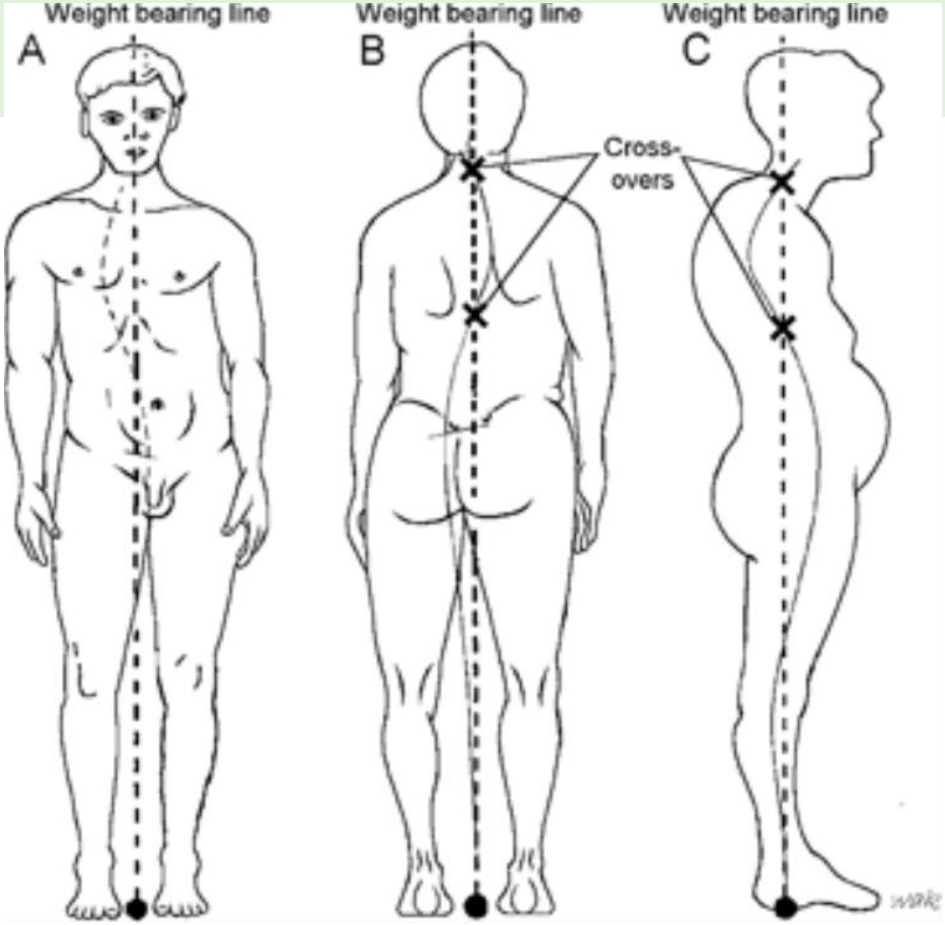

Legend:

Postural crossover sites. (Courtesy of William Kuchera, D.O., F.A.A.O.)

From: **Postural Considerations in Osteopathic Diagnosis and Treatment**

Foundations of Osteopathic Medicine, 3e, 2010

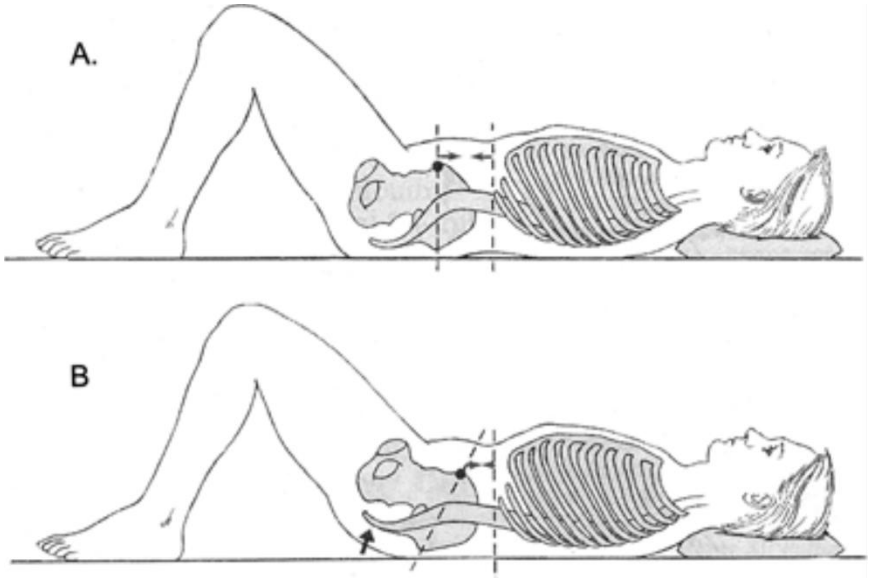

Legend:

Lumbar lordosis, with patient actively attempting to flatten spine to table.A Structural component (no reduction of lordotic curve). B Flattening indicative of functional lordotic curve. (From Simon DG, Travell JG, Simons LS. Myofascial Pain and Dysfunction: The Trigger Point Manual. Vol I. Baltimore, MD: Williams & Wilkins, 1999, with permission.)

Behavioral Model

- The complex cognitive, emotional, behavioral, and habitual aspects of disease and health.
- This model seeks treatment through building rapport, sharing information and behavioral therapy.
- Distress has been shown to worsen outcomes in many chronic diseases.

Attention to posture
Appropriate exercise
Emotional reactions & social support
Habits
Pacing oneself

From: **Clinical Decision Making**

Foundations of Osteopathic Medicine, 3e, 2010

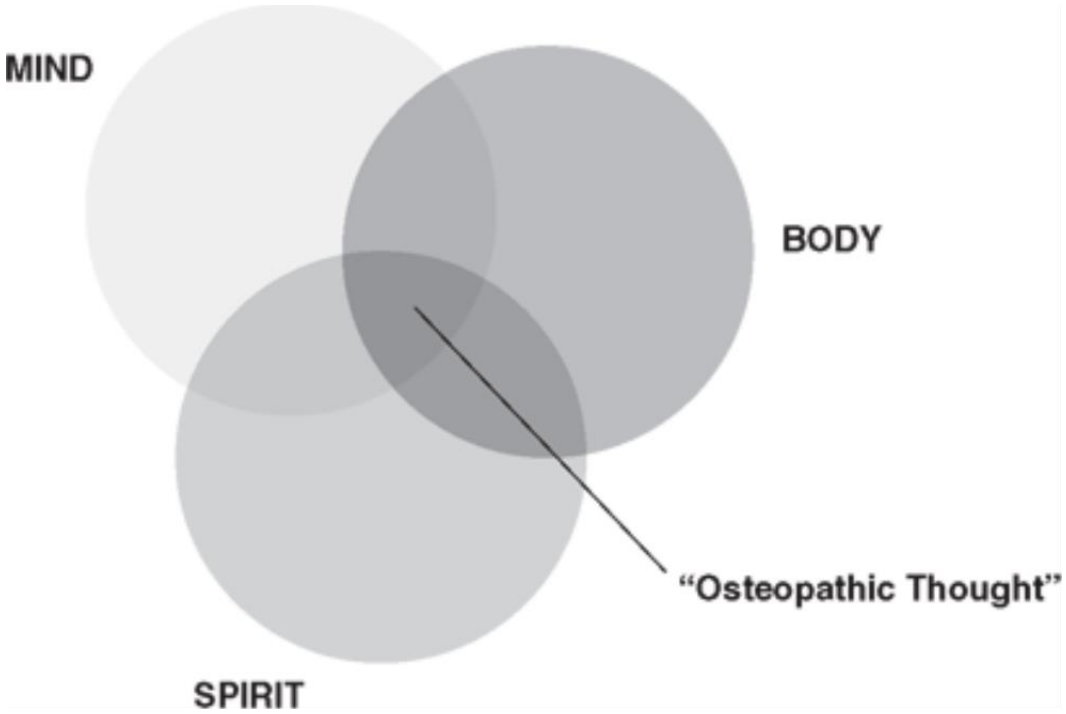

Legend:

Identifying the origin of osteopathic thought.

Additional Management

- Trigger point injections
- Prolotherapy and regenerative medicine
  - Prolotherapycollege.org